

90

Diagnosis and management of head and neck cancer

Quick Reference Guide

**October 2006**

ALL HEAD AND NECK CANCERS

REDUCING RISK

The risk of having head and neck cancer can be reduced by:

- B ▪ not smoking or chewing tobacco
- B ▪ limiting alcohol consumption, in line with government guidelines
- C ▪ increasing the intake of fruit and vegetables (specifically tomatoes), olive oil and fish oils
- C ▪ reducing the intake of red meat, fried food and fat.

PRESENTATION AND SCREENING

All healthcare practitioners, including dental and medical practitioners, should be aware of the presenting features of head and neck cancer, and the local referral pathways for suspected cancers.

Dental practitioners should include a full examination of the oral mucosa as part of routine dental check up.

B Leaflets about signs, symptoms and risks of head and neck cancer should be available in primary care.

REFERRAL

B Rapid access or “one stop” clinics should be available for patients who fulfil appropriate referral criteria.

Patients should be seen within two weeks of urgent referral.

DIAGNOSIS AND STAGING

D Fine needle aspiration cytology should be used in the investigation of head and neck masses.

D All patients with head and neck cancer should have direct pharyngolaryngoscopy and chest X-ray with symptom-directed endoscopy where indicated.

D

- CT or MRI of the primary tumour site should be performed to help define the T stage of the tumour.
- MRI should be used to stage oropharyngeal and oral tumours.

D MRI should be used in assessing:

- laryngeal cartilage invasion
- tumour involvement of the skull base, orbit, cervical spine or neurovascular structures (most suprahypoid tumours).

ALL HEAD AND NECK CANCERS

DIAGNOSIS AND STAGING (cont)

D CT or MRI from skull-base to sternoclavicular joints should be performed in all patients at the time of imaging the primary tumour to stage the neck for nodal metastatic disease.

B Where the nodal staging on CT or MRI is equivocal, USFNA and/or FDG-PET increase the accuracy of nodal staging.

D All patients with head and neck cancer should undergo CT of the thorax.

C FDG-PET should be performed as the next investigation of choice in patients presenting with:

- cervical lymph node metastases, where CT or MRI does not demonstrate an obvious primary tumour.
- suspected recurrent head and neck cancer, where CT/MRI does not demonstrate a clear cut recurrence.

HISTOPATHOLOGY REPORTING

C Histopathology reporting of specimens from the primary site of head and neck cancer should include:

- tumour site
- tumour grade
- maximum tumour dimension
- maximum depth of invasion
- margin involvement by invasive and/or severe dysplasia
- pattern of infiltration
- perineural involvement

D ▪ tumour type

▪ lymphatic/vascular permeation.

C Histopathology reporting of specimens from areas of metastatic disease in patients with head and neck cancer should include:

- number of involved nodes
- level of involved nodes
- extracapsular spread of tumour

▪ type of nodal dissection
▪ size of largest tumour mass.

ALL HEAD AND NECK CANCERS

DEFINITIONS

Laryngeal cancer includes tumours of the:

- supraglottis
- glottis
- subglottis.

Hypopharyngeal cancer includes tumours of the:

- postcricoid area
- pyriform sinus
- posterior pharyngeal wall.

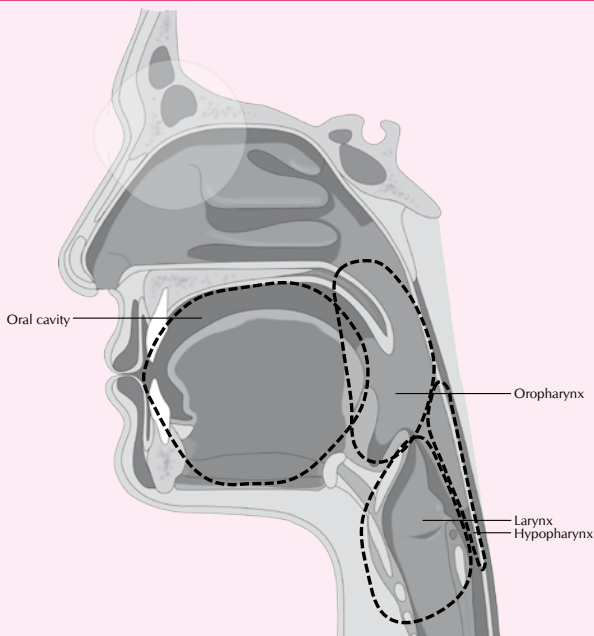
Oropharyngeal cancer includes tumours of the:

- base of tongue
- tonsil
- soft palate.

Oral cavity cancer includes tumours of the:

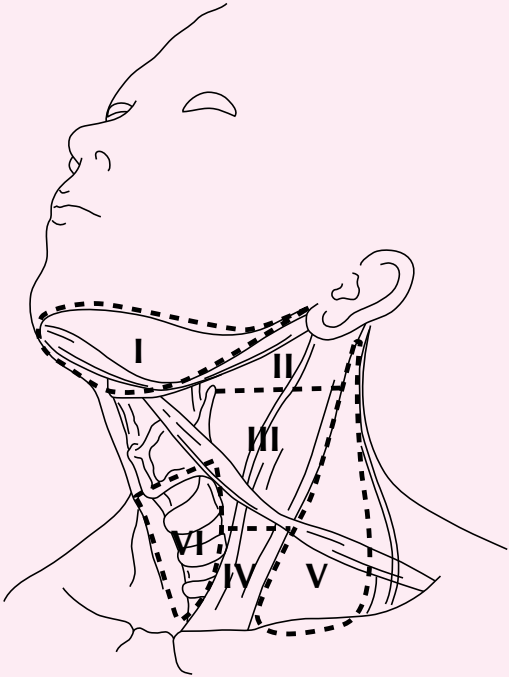
- buccal mucosa
- retromolar triangle
- alveolus
- hard palate
- anterior two-thirds of tongue
- floor of mouth
- mucosal surface of the lip.

DIAGRAM OF THE HEAD AND NECK



ALL HEAD AND NECK CANCERS

DIAGRAM OF THE LYMPH NODES LEVELS IN THE NECK



NECK DISSECTION TECHNIQUES

Comprehensive neck dissection

Radical neck dissection

All ipsilateral lymph nodes from level I-V are removed along with the spinal accessory nerve, internal jugular vein and sternocleidomastoid muscle.

Modified radical neck dissection

As for radical neck dissection with preservation of one or more non-lymphatic structures. This is sometimes referred to as a "functional" neck dissection.

Selective neck dissection

One or more of the lymphatic groups normally removed in the radical neck dissection is preserved. The lymph node groups removed are based on patterns of metastases which are predictable for each site of the disease.

Extended neck dissection

Additional lymph node groups or non-lymphatic structures are removed.

LARYNGEAL CANCER

▶ Early glottic cancer

- D** Patients with early glottic cancer may be treated either by external beam radiotherapy or conservation surgery:
- B**
- external beam radiotherapy in short fractionation regimens with fraction size $> 2\text{Gy}$ (eg 53-55Gy in 20 fractions over 28 days or 50-52Gy in 16 fractions over 22 days) and without concurrent chemotherapy
- D**
- either endoscopic laser excision or partial laryngectomy.

D Prophylactic treatment of the neck nodes is not required.

▶ Early supraglottic cancer

- D** Patients with early supraglottic cancer may be treated by either external beam radiotherapy or conservation surgery:
- radiotherapy should include prophylactic bilateral treatment of level II- III lymph nodes in the neck
 - endoscopic laser excision or supraglottic laryngectomy with selective neck dissection to include level II-III nodes should be considered
 - neck dissection should be bilateral if the tumour is not well lateralised.

NOTES

LARYNGEAL CANCER

Locally advanced laryngeal cancer

A Patients with locally advanced resectable laryngeal cancer should be treated by:

- total laryngectomy with or without postoperative radiotherapy
- an initial organ preservation strategy reserving surgery for salvage.

A

- Treatment for organ preservation or non-resectable disease should be concurrent chemoradiation with single agent cisplatin.
- In patients medically unsuitable for chemotherapy, concurrent administration of cetuximab with radiotherapy should be considered.
- Radiotherapy should only be used as a single modality when comorbidity precludes the use of concurrent chemotherapy, concurrent cetuximab or surgery.
- Where radiotherapy is being used as a single modality without concurrent chemotherapy or cetuximab, a modified fractionation schedule should be considered.

D In patients with clinically N0 disease, nodal levels II-IV should be treated prophylactically by:

- surgery (*selective neck dissection*)
- external beam radiotherapy.

If the tumour is not well lateralised both sides of the neck should be treated.

D Patients with a clinically node positive neck should be treated by:

- modified radical neck dissection, with postoperative chemoradiotherapy or radiotherapy when indicated
- chemoradiotherapy followed by neck dissection when there is clinical evidence of residual disease following completion of therapy (*N1 disease*)
- chemoradiotherapy followed by planned neck dissection (*N2 and N3 disease*).

The target volume should include neck nodal levels II-IV.

D

- Postoperative radiotherapy should be considered for patients with clinical and pathological features that indicate a high risk of recurrence.

A

- Administration of cisplatin chemotherapy concurrently with postoperative radiotherapy should be considered, particularly in patients with extracapsular spread and/or positive surgical margins.

HYPOPHARYNGEAL CANCER

▶ Early hypopharyngeal cancer

D Patients with early hypopharyngeal cancer may be treated by:

- radical external beam radiotherapy with concomitant cisplatin chemotherapy and prophylactic irradiation of neck nodes (*levels II-IV bilaterally*)
- conservative surgery and bilateral selective neck dissection (*levels II-IV, where local expertise is available*)
- radiotherapy (*patients unsuitable for concurrent chemoradiation or surgery*).

D ▪ Consider postoperative radiotherapy for patients with clinical and pathological features that indicate a high risk of recurrence.

A ▪ Consider administration of cisplatin chemotherapy concurrently with postoperative radiotherapy, particularly in patients with extracapsular spread and/or positive surgical margins.

▶ Locally advanced hypopharyngeal cancer

A Patients with resectable locally advanced hypopharyngeal cancer may be treated either by surgical resection or an organ preservation approach.

A ▪ For patients with resectable locally advanced hypopharyngeal cancer who wish to pursue an organ preservation strategy, consider external beam radiotherapy with concurrent cisplatin chemotherapy.

A ▪ Neoadjuvant cisplatin/5FU followed by radical radiotherapy alone may be used in patients who have a complete response to chemotherapy.

D ▪ Patients with resectable locally advanced disease should not be treated by radiotherapy alone unless comorbidity precludes both surgery and concurrent chemotherapy.

NOTES

HYPOPHARYNGEAL CANCER

Locally advanced hypopharyngeal cancer (cont)

A Patients with unresectable disease should be treated by external beam radiotherapy with concurrent cisplatin chemotherapy.

- A**
- In patients medically unsuitable for chemotherapy, consider concurrent administration of cetuximab with radiotherapy.
 - Single modality radiotherapy without concurrent chemotherapy should follow a modified fractionation schedule.

D Patients with a clinically N0 neck should undergo prophylactic treatment of the neck, either by selective neck dissection or radiotherapy, including nodal levels II-IV bilaterally.

- D** Patients with a clinically node positive neck should be treated by:
- modified radical neck dissection, with postoperative chemoradiotherapy or radiotherapy when indicated
 - chemoradiotherapy followed by neck dissection when there is clinical evidence of residual disease following completion of therapy (*N1 disease*)
 - chemoradiotherapy followed by planned neck dissection (*N2 and N3 disease*).
- The target volume should include neck nodal levels II-IV.

D In patients with a small primary tumour, locally advanced nodal disease may be resected prior to treating the primary with definitive radiotherapy and the neck with adjuvant radiotherapy (*both with or without chemotherapy*).

D ▪ Postoperative radiotherapy should be considered for patients with clinical and pathological features that indicate a high risk of recurrence.

A ▪ Consider concurrent administration of cisplatin chemotherapy with postoperative radiotherapy, particularly in patients with extracapsular spread and/or positive surgical margins.

OROPHARYNGEAL CANCER

Early oropharyngeal cancer

D Patients with early oropharyngeal cancer may be treated by:

- **primary resection, with reconstruction as appropriate, and neck dissection** (*selective neck dissection encompassing nodal levels II-IV, or II-V if base of tongue*)
- **external beam radiotherapy encompassing the primary tumour and neck nodes** (*levels II-IV, or levels II-V if base of tongue*).

- D**
- Patients with small accessible tumours may be treated by a combination of external beam radiotherapy and brachytherapy in centres with appropriate expertise.
 - In patients with well-lateralised tumours prophylactic treatment of the ipsilateral neck only is required.
 - Bilateral treatment of the neck is recommended when the incidence of occult disease in the contralateral neck is high (*tumour is encroaching on base of tongue or soft palate*).

D ▪ Postoperative radiotherapy should be considered for patients with clinical and pathological features that indicate a high risk of recurrence.

A ▪ Administration of cisplatin chemotherapy concurrently with postoperative radiotherapy should be considered, particularly in patients with extracapsular spread and/or positive surgical margins.

NOTES

OROPHARYNGEAL CANCER

Locally advanced oropharyngeal cancer

- D** Patients with advanced oropharyngeal cancer may be treated by primary surgery (*if a clear surgical margin can be obtained*).
- D** ▪ Patients who have a clinically node positive neck should have a modified radical neck dissection.
- D** ▪ Postoperative chemoradiotherapy to the primary site and neck should be considered for patients who show high risk pathological features.
- A** ▪ Administration of cisplatin chemotherapy concurrently with postoperative radiotherapy should be considered in patients with extracapsular spread and/or positive surgical margins.

- D** Patients with advanced oropharyngeal cancer may be treated by an organ preservation approach.
- A** ▪ Radiotherapy should be administered with concurrent cisplatin chemotherapy.
- D** ▪ The primary tumour and neck node levels (II-V) should be treated bilaterally.
- A** ▪ In patients medically unsuitable for chemotherapy, concurrent administration of cetuximab with radiotherapy should be considered.
- A** ▪ Where radiotherapy is being used as a single modality without concurrent chemotherapy or cetuximab, a modified fractionation schedule should be considered.
- D** ▪ Patients with N1 disease should be treated with chemoradiotherapy followed by neck dissection where there is clinical evidence of residual disease following completion of therapy.
- D** ▪ Patients with N2 and N3 nodal disease should be treated with chemoradiotherapy followed by planned neck dissection.
- D** ▪ In patients with a small primary tumour, locally advanced nodal disease may be resected prior to treating the primary with definitive chemoradiotherapy and the neck with adjuvant chemoradiotherapy.

ORAL CAVITY CANCER

▶ Early oral cavity cancer

- D** Patients with oral cavity cancer may be treated by:
- surgical resection, where rim rather than segmental resection should be performed, where possible, in situations where removal of bone is required to achieve clear histological margins
 - brachytherapy in accessible well demarcated lesions.

- D** Re-resection should be performed to achieve clear histological margins if the initial resection has positive surgical margins.

- D**
- The clinically **N0** neck (*levels I-III*) should be treated prophylactically either by external beam radiotherapy or selective neck dissection.
 - Postoperative radiotherapy should be considered for patients who have positive nodes after pathological assessment.

- D**
- Postoperative radiotherapy should be considered for patients with clinical and pathological features that indicate a high risk of recurrence.
- A**
- Administration of cisplatin chemotherapy concurrently with postoperative radiotherapy should be considered, particularly in patients with extracapsular spread and/or positive surgical margins.

NOTES

ORAL CAVITY CANCER

▶ Advanced oral cavity cancer

D Patients with resectable disease who are fit for surgery should have surgical resection with reconstruction.

- D**
- Patients with node positive disease should be treated by modified radical neck dissection.
 - Elective dissection of the contralateral neck should be considered if the primary tumour is locally advanced, arises from the midline or there are multiple ipsilateral nodes involved.

- A** Radical external beam radiotherapy with concurrent cisplatin chemotherapy should be considered when:
- the tumour cannot be adequately resected
 - the patient's general condition precludes surgery
 - the patient does not wish to undergo surgical resection.
- D**
- Nodal levels I-IV should be irradiated bilaterally.

- D**
- Patients with N1 disease who are receiving radiotherapy to the primary tumour should be treated with chemoradiotherapy where there is clinical evidence of residual disease following completion of therapy.
 - Patients with N2 and N3 nodal disease who are receiving radiotherapy to the primary tumour should be treated with chemoradiotherapy followed by planned neck dissection.

- A**
- In patients medically unsuitable for chemotherapy, concurrent administration of cetuximab with radiotherapy should be considered.
 - Where radiotherapy is being used as a single modality without concurrent chemotherapy or cetuximab, a modified fractionation schedule should be considered.

D

- Postoperative radiotherapy should be considered for patients with clinical and pathological features that indicate a high risk of recurrence.

A

- Administration of cisplatin chemotherapy concurrently with postoperative radiotherapy should be considered, particularly in patients with extracapsular spread and/or positive surgical margins.

ALL HEAD AND NECK CANCERS

MANAGEMENT OF RADIATION SIDE EFFECTS

A Patients with oral cavity, laryngeal, oropharyngeal or hypopharyngeal tumours who are being treated with radiotherapy should be offered benzydamine oral rinse before, during, and up to three weeks after completion of radiotherapy.

A Pilocarpine (5-10 mg three times per day) may be offered to improve radiation-induced xerostomia following radiotherapy to patients with evidence of some intact salivary function, providing there are no medical contraindications to its use.

MANAGEMENT OF LOCOREGIONAL RECURRENCE

- D**
- Salvage surgery should be considered in any patient with a resectable locoregional recurrence of oral cavity, oropharyngeal, laryngeal or hypopharyngeal cancer following previous radiotherapy or surgery.
 - Selected patients who have unresectable locally recurrent disease following previous radiotherapy may be considered for potentially curative re-irradiation.
 - Patients with small accessible recurrences in a previously irradiated region may be considered for interstitial brachytherapy in centres with appropriate facilities and expertise.

PALLIATION OF INCURABLE DISEASE

Short term toxicity and length of hospital stay should be balanced against likely symptomatic relief.

- A**
- Patients of adequate performance status should be considered for palliative chemotherapy which may reduce tumour volume.
 - Single agent methotrexate, single agent cisplatin, or cisplatin/5FU combination should be considered for palliative chemotherapy in patients with head and neck cancer.
 - Excessive toxicity from intensive chemotherapeutic combination regimens should be avoided.

D Radiotherapy may be considered for palliative treatment in patients with locally advanced incurable head and neck cancer.

Appropriate surgical procedures should be considered for palliation of particular symptoms, taking local expertise into consideration.

ALL HEAD AND NECK CANCERS

FOLLOW UP

D Patients should be seen frequently and regularly within the first three years post-treatment.

- C**
- Patients' weight should be monitored at follow up.
 - Patients' complaints of pain should be investigated.

▶ Oral and dental rehabilitation

- C**
- Patients receiving oral surgery or radiotherapy to the mouth (*with or without adjuvant chemotherapy*) should have post-treatment dental rehabilitation.
 - Patients should access lifelong dental follow up and dental rehabilitation.
 - Dental extractions in irradiated jaws should be carried out in hospital by a specialist practitioner.
 - Hyperbaric oxygen facilities should be available for selected patients.

- Patients should have access to a consultant restorative dentist.

▶ Speech and language therapy

C Head and neck cancer patients with dysphagia should receive appropriate speech and language therapy to optimise residual swallow function and reduce aspiration risk.

C All patients with oral, oropharyngeal, hypopharyngeal and laryngeal cancer should have access to instrumental investigation for dysphagia.

- C** Patients should have access to a specialist speech and language therapist:
- before, during and after chemoradiation treatment
 - soon after diagnosis and before treatment commences, where communication problems are likely to occur
 - when undergoing laryngectomy to restore voice either by a tracheoesophageal voice prosthesis and/or oesophageal speech.

▶ Nutritional support

- All head and neck cancer patients should be screened at diagnosis for nutritional status using a validated screening tool appropriate to the patient population.

C After screening, at-risk patients should receive early intervention for nutritional support by an experienced dietitian.

ABBREVIATIONS

5FU	5-fluorouracil
FDG-PET	fluorodeoxy glucose positron emission tomography
Gy	Gray
CT	computerised tomography
MRI	magnetic resonance imaging
N0	node negative
USFNA	ultrasound guided fine needle aspiration

This Quick Reference Guide provides a summary of the main recommendations in the SIGN guideline on the **Diagnosis and management of head and neck cancer**.

Recommendations are graded **A B C D** to indicate the strength of the supporting evidence.

Good practice points are provided where the guideline development group wishes to highlight specific aspects of accepted clinical practice.

Details of the evidence supporting these recommendations can be found in the full guideline, available on the SIGN website: www.sign.ac.uk

ISBN (10) 1 905813 12 0

ISBN (13) 978 1 905813 12 4

Scottish Intercollegiate Guidelines Network
28 Thistle Street, Edinburgh EH2 1EN

www.sign.ac.uk